



Glenoid inclination: In vivo measures in rotator cuff tear patients and associations with superior glenohumeral joint translation

Jennifer L. Bishop, MS, Stephanie K. Kline, MS, Kristopher J. Aalderink, MD, Roger Zuel, MS, Michael J. Bey, PhD*

Department of Orthopaedic Surgery, Bone and Joint Center, Henry Ford Hospital, Detroit, MI

Summary Glenoid inclination has been associated with rotator cuff tears and superior humeral translation, but the relationship between glenoid inclination and superior humeral translation has not been assessed in vivo. This study compared glenoid inclination between repaired and contralateral shoulders in 21 unilateral rotator cuff repair patients. As a secondary analysis, we assessed the relationship between glenoid inclination and in vivo superior humeral translation. Glenoid inclination was measured from patient-specific, computed tomography-based bone models. Glenohumeral joint motion was measured from biplane radiographs collected during coronal-plane abductions. Glenoid inclination was significantly lower for the rotator cuff tear shoulders (90.7°) than the asymptomatic, contralateral shoulders (92.3° , $P = .04$). No significant correlation existed between increased glenoid inclination and superior–inferior translation of the uninjured shoulder ($P > .30$). This study failed to support the theory that glenoid inclination is responsible for superior humeral translation and the development of subacromial impingement.

© 2009 Journal of Shoulder and Elbow Surgery Board of Trustees.

Rotator cuff injuries are very common, leading to pain, loss of function, and significant medical expense. The etiology of rotator cuff injuries is not well understood, but subacromial impingement has long been associated with rotator cuff disability.⁷⁻⁹ Subacromial impingement has been associated with superior translation of the humerus relative to the scapula,^{10,15} and it is also believed that glenoid inclination (ie, the degree to which the glenoid is

tipped up relative to the scapula) may influence the amount of superior humeral translation.

The belief that increased glenoid inclination leads to superior translation of the humerus and ultimately subacromial impingement is supported by previous data. Specifically, cadaveric studies have demonstrated that greater glenoid inclination is associated with higher superior translation of the humerus,^{6,13} and imaging studies have demonstrated greater glenoid inclination in the shoulders of patients or those from deceased donors with rotator cuff tears.^{4,12} In contrast, a study by Kandemir et al⁵ failed to detect any significant difference in glenoid inclination between cadaveric specimens with a rotator cuff injury and specimens with a normal, healthy rotator cuff. Furthermore, the relationship between glenoid inclination

The project was supported by grant number AR051912 from National Institutes of Health (NIH)/National Institute of Arthritis and Musculoskeletal and Skin Diseases (NIAMS).

*Reprint requests: Michael Bey, PhD, Henry Ford Hospital, Department of Orthopaedic Surgery, Bone and Joint Center, 2799 W Grand Blvd; E&R 2015, Detroit, MI 48202.

E-mail address: bey@bjc.hfh.edu (M.J. Bey).

and superior humeral translation has been demonstrated only in cadaveric studies, where it is extremely difficult to accurately simulate the complex muscle forces and joint forces that occur during in-vivo conditions.

Thus, the relationship between glenoid inclination and glenohumeral joint translation under in vivo conditions remains unknown. The primary objective of this study was to compare glenoid inclination between the repaired and contralateral shoulders of patients who had undergone unilateral rotator cuff repair. We hypothesized that the repaired shoulder would have greater glenoid inclination than the contralateral shoulder. As a secondary analysis of these data, we assessed the relationship between glenoid inclination and in vivo superior translation of the humerus relative to the scapula. We hypothesized that there would be a significant association between glenoid inclination and superior translation of the humerus during shoulder elevation.

Materials and methods

After Institutional Review Board approval and informed consent, 21 individuals (14 men, 7 women, age 63.0 ± 11.4 years) were included in this study. The sample size of 21 patients was based on a standard deviation of 2.3° (from preliminary data collected as part of this study) and the desire to detect a difference in glenoid inclination of 1.5° with 80% power ($\alpha = 0.05$, $\beta = 0.2$). Each participant underwent arthroscopic surgery on 1 shoulder 4 months before the study to repair a full-thickness supraspinatus tendon tear. The contralateral shoulder of each subject was asymptomatic and was deemed to be normal under clinical exam by an orthopedic surgeon.

Glenoid inclination (ie, superior–inferior tilt of the glenoid relative to the scapula) was measured in both shoulders of each subject using subject-specific, computed tomography (CT)-based, three-dimensional (3D) computer models. To achieve this, individual CT scans of the entire left and right scapula and humerus were acquired for each patient (GE Lightspeed16, Milwaukee, WI). Each CT scan had an in-plane resolution of approximately 0.6×0.6 mm and a slice spacing of 1.25 mm. The humerus and scapula were segmented from surrounding soft tissues (Mimics 11.11, Materialise, Leuven, Belgium) and then reconstructed into a 3D computer model.

Custom software was used to manually define anatomic landmarks on each CT model and to calculate glenoid inclination, as previously reported (Figure 1).^{4,5} These anatomic landmarks included (1) the intersection of the scapular spine and the scapula's medial border, (2) the middle of the spinoglenoid notch, (3) the superior-most point on the glenoid rim, and (4) the inferior-most point on the glenoid rim. The glenoid inclination angle was defined as the 3D angle between a line connecting the intersection of the scapular spine and the medial border (Figure 1, point A) to the spinoglenoid notch (Figure 1, point B), and a line connecting the superior glenoid rim (Figure 1, point C) and inferior glenoid rim (Figure 1, point D). A greater inclination angle indicates a more superior-facing glenoid relative to the scapula. One observer identified all landmarks for all study participants. In addition, these landmarks were identified 2 more times on 12 of the CT models, with the observer masked to previous measurements. These data provided an assessment of intraobserver reliability.

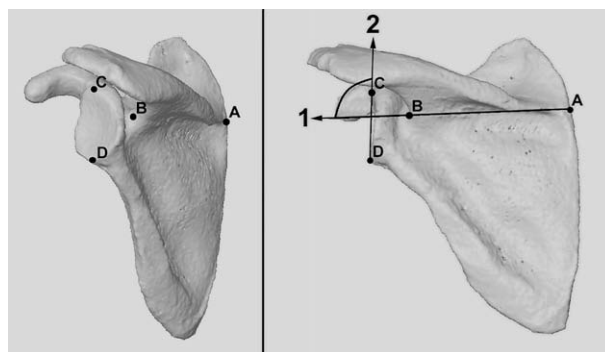


Figure 1 Glenoid inclination angle was calculated as the angle formed between line 1 and line 2. *Line 1* was defined as connecting (A) the intersection of the scapular spine with the scapula's medial border and (B) the middle of the spinoglenoid notch. *Line 2* was defined as connecting (C) the superior-most point on the glenoid rim and (D) the inferior-most point on the glenoid rim.

Dynamic in vivo glenohumeral joint motion was determined by measuring the 3D position of the humerus and scapula from images acquired with a biplane x-ray system during shoulder abduction. To accomplish this, the participant's shoulder was centered within a biplane x-ray system.¹¹ The system consisted of two 100-kW pulsed x-ray generators (EMD Technologies CPX 3100CV, Saint-Eustache, Quebec, Canada) and two 30-cm image intensifiers (AI5765HVP, Shimadzu Corporation, Kyoto, Japan), optically coupled to synchronized high-speed video cameras (Phantom IV, Vision Research, Wayne, NJ). Subjects wore a lead-lined thyroid shield and a protective vest during testing to minimize x-ray exposure. Biplane x-ray images were acquired at 60 Hz while each subject abducted his or her shoulder in the frontal plane from full adduction to approximately 120° of humerothoracic elevation. This motion was performed with each participant holding a 3-pound hand weight or a weight consistent with the individual's stage of rehabilitation. Three trials were recorded for each shoulder, both shoulders were tested, and the testing order was randomized.

The 3D positions of the humerus and scapula throughout each trial were measured from the biplane x-ray images using an accurate (± 0.4 mm, $\pm 0.5^\circ$), model-based tracking technique.³ Custom software was used to identify the 3D locations of major anatomic landmarks on the humeral and scapular models and to define standard coordinate system axes.¹⁴ Consistent with conventional techniques for measuring shoulder motion, translations were expressed in terms of the position of the center of the humeral head relative to the origin of the scapular coordinate system.

Using these data, we calculated 3 specific outcome measures to characterize superior–inferior (SI) translation of the center of the humeral head relative to the scapula. The outcome measures included humeral head center SI translation range (HHC RANGE), SI translation from the adducted starting position to full abduction (HHC ABD), and maximum superior translation relative to the adducted starting position (HHC MAX; Figure 2). Although these 3 outcome measures are related, they were specifically chosen because the SI position of the humeral head center does not necessarily increase monotonically with shoulder abduction.²

As an alternative approach for quantifying in vivo glenohumeral joint translation, we also calculated translation of the center of contact between the articulating surfaces of the humerus and glenoid. This was accomplished with a technique that estimates joint contact

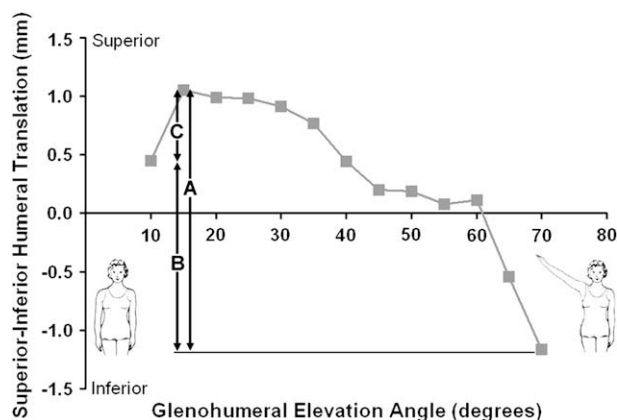


Figure 2 Data from a representative subject shows how the superior–inferior position of the humeral head center changes relative to the scapula with elevation angle. The superior–inferior motion of the humeral head center was characterized for each subject in terms of: (A) superior–inferior translation range, (B) superior–inferior translation from the adducted starting position to full abduction, and (C) maximum superior translation relative to the adducted starting position.

patterns by combining joint motion measured from the biplane x-ray images with the subject-specific bone models.¹ Specifically, the glenohumeral joint contact center location was determined by first calculating the distance between the articulating surfaces of the humerus and glenoid and then calculating the centroid of the closest 200 mm² region of contact between the humerus and glenoid. The 3D coordinates of this contact center location were expressed relative to the origin of the scapula coordinate system. These data were calculated for every frame of each trial, producing a contact center path whose position on the glenoid varied as the arm was abducted. Owing to differences in glenoid size between subjects, these joint contact data were normalized relative to the size of each subject's glenoid. Specifically, the 3D coordinate data were expressed as a percentage of the anterior–posterior (AP) glenoid dimension and the SI glenoid dimension (ie, the distance from point C to D in Figure 1). Using these data, we calculated 3 specific outcome measures to characterize SI translation of the joint contact center relative to the glenoid. The outcome measures included the contact center SI translation range (CC RANGE), contact center SI translation from the adducted starting position to full abduction (CC ABD), and contact center maximum superior translation relative to the adducted starting position (CC MAX) (Figure 3). Although these 3 outcome measures are related, they were specifically chosen because the SI position of the joint contact center does not necessarily increase monotonically with shoulder abduction.

Thus, a total of 6 measures of in vivo glenohumeral joint translation were collected. Three of these outcome measures were based on the SI translation of the center of the humeral head (ie, HHC RANGE, HHC ABD, and HHC MAX), and three of the outcome measures were based on the SI translation of the glenohumeral joint contact center (ie, CC RANGE, CC ABD, and CC MAX).

Statistical analysis

The intraclass correlation coefficient was calculated to determine the reliability of the glenoid inclination measurement. The effect

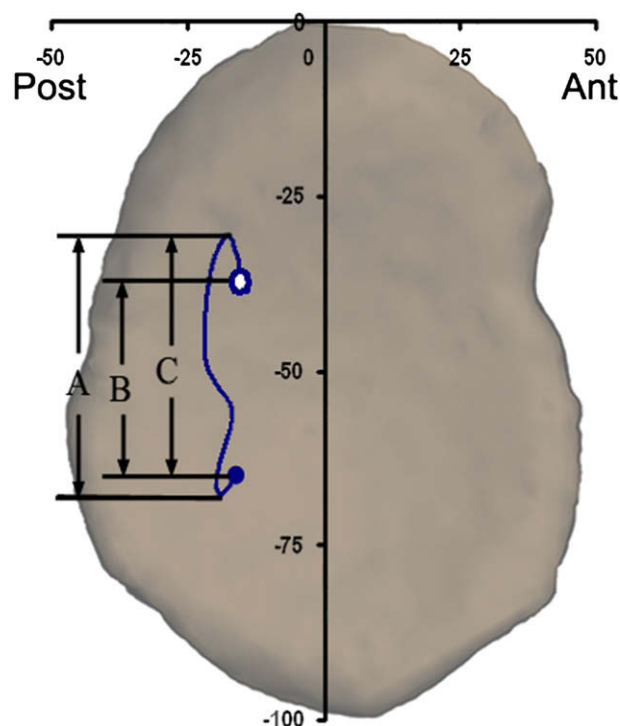


Figure 3 Data from a representative subject shows how the glenohumeral joint contact center position changed during elevation from the adducted starting position (*closed circle*) to approximately 120° of humerothoracic abduction (*open circle*). Superior–inferior motion of the contact center was characterized for each subject in terms of (A) superior–inferior translation range, (B) superior–inferior translation from the adducted starting position to full abduction, and (C) maximum superior translation relative to the adducted starting position.

of shoulder condition (repaired vs contralateral) on glenoid inclination was assessed with a paired *t* test. The association between glenoid inclination and each of the 6 outcome measures of glenohumeral joint translation SI translation was assessed for only the contralateral shoulder with linear regression and a correlation coefficient. Significance for all statistical tests was set at $P < .05$.

Results

The intraclass correlation coefficient of glenoid inclination angle measurements was 0.94. Glenoid inclination was an average of $1.6^\circ \pm 3.3^\circ$ lower in the repaired shoulder than in the contralateral shoulder ($P = .04$, Figure 4). There was considerable variation across subjects in the difference in glenoid inclination between shoulders. Specifically, the individual results demonstrated that glenoid inclination in the asymptomatic shoulder ranged from 7.4° higher to 5.2° lower than the repaired shoulder (Figure 5). Glenoid inclination in 14 subjects was greater in the asymptomatic shoulder, 6 had greater glenoid inclination in the repaired shoulder, and 1 had no difference in glenoid inclination between the repaired and contralateral shoulders (Figure 5).

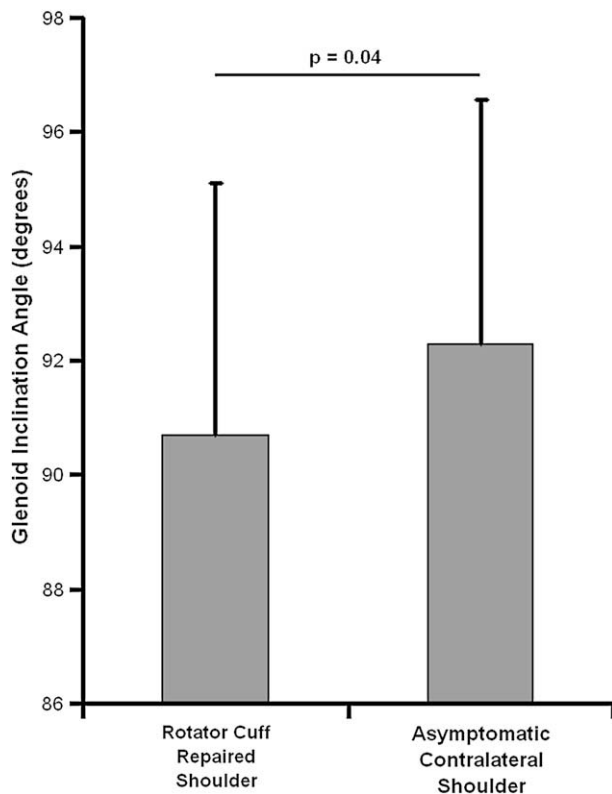


Figure 4 The average (\pm standard deviation) glenoid inclination in the shoulder with the repaired rotator cuff was significantly less than in the asymptomatic contralateral shoulder ($P = .04$).

A weak association was found between glenoid inclination and the three measures of SI translation based on the position of the center of the humeral head (Table I). Specifically, no statistically significant association was detected between glenoid inclination and HHC RANGE ($r = -0.25$, $P = .30$), HHC MAX ($r = 0.02$, $P = .95$), or HHC ABD ($r = -0.25$, $P = .30$). Similarly, the association between glenoid inclination and the 3 measures of SI translation based on the joint contact center data was also weak (Table I). Specifically, no statistically significant association was detected between glenoid inclination and CC RANGE ($r = -0.10$, $P = .67$), CC MAX ($r = -0.16$, $P = .50$), or CC ABD ($r = 0.22$, $P = .37$).

Discussion

The primary objective of this study was to compare glenoid inclination between the repaired and contralateral shoulders of patients who had a unilateral rotator cuff tear. As a secondary analysis, we assessed the association between glenoid inclination and in vivo glenohumeral joint translation. We found a statistically significant difference in glenoid inclination between the repaired and contralateral shoulders ($P = .04$). However, none of the associations between glenoid inclination and the 6 measures of SI glenohumeral translation were statistically significant ($P > .30$).

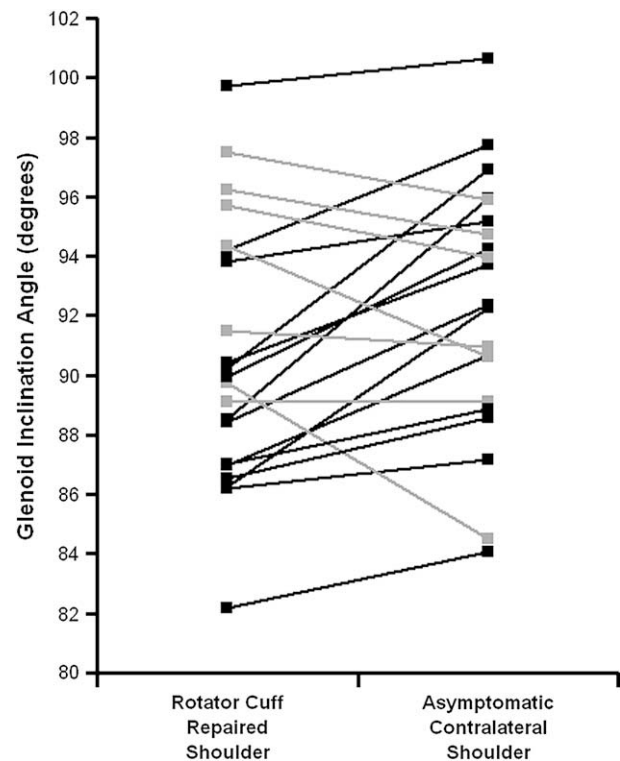


Figure 5 Individual glenoid inclination measurements for each of the 21 subjects. Participants whose glenoid inclination was highest in the contralateral shoulder are shown in *black*, and those whose glenoid inclination in the repaired shoulder was greater than or equal to their contralateral shoulder are shown in *gray*.

The finding that glenoid inclination in the rotator cuff tear shoulder (90.7°) was lower than that of the asymptomatic, contralateral shoulder (92.3°) was somewhat surprising, particularly in light of previous research that has demonstrated that rotator cuff tears are associated with higher glenoid inclination. This finding has been supported by both cadaveric studies⁴ and imaging studies of patients with rotator cuff tears.¹² Furthermore, the reported differences in glenoid inclination between specimens or patients with rotator cuff tears and those without cuff tears were not trivial. Hughes et al⁴ reported a difference in glenoid inclination of 7.6° , whereas Tetreault et al¹² reported a difference in glenoid inclination of 10° . In contrast to these findings, a study by Kandemir et al⁵ failed to detect any significant difference in glenoid inclination between 12 cadaveric specimens with a full-thickness rotator cuff tear and 12 specimens with no injury. Thus, conflicting results have been published on the association between glenoid inclination and rotator cuff tears. To our knowledge, the current study is the first investigation to report lower glenoid inclination in patients with rotator cuff tears.

It is possible that the discrepancy in results between this and previous studies on the association between glenoid inclination and rotator cuff tears may be partly explained by differences in measurement techniques. In particular, 2D measurement techniques, such as the radiographic images

Table I Association between glenoid inclination and the 6 specific outcome measures of in vivo superior–inferior humeral translation^a

Outcome measure	Correlation coefficient (95% CI)	P
HHC RANGE	−0.25 (−0.63 to 0.23)	.30
HHC MAX	0.01 (−0.44 to 0.47)	.95
HHC ABD	−0.25 (−0.63 to 0.23)	.30
CC RANGE	−0.10 (−0.53 to 0.37)	.67
CC MAX	−0.16 (−0.58 to 0.31)	.50
CC ABD	−0.22 (−0.61 to 0.26)	.37

CC ABD, contact center superior–inferior translation from the adducted starting position to full abduction; CC MAX, contact center maximum superior translation relative to the adducted starting position; CC RANGE, contact center superior–inferior translation range; HHC ABD, Humeral head center superior–inferior translation from the adducted starting position to full abduction; HHC MAX, maximum superior translation relative to the adducted humeral head center starting position; HHC RANGE, humeral head center superior–inferior translation range.

^a No statistically significant association was found between glenoid inclination and in vivo superior–inferior humeral translation ($P > .05$).

used by Hughes et al⁴ and the magnetic resonance images used by Tetreault et al,¹² are likely susceptible to subtle errors in alignment of the specimen or patient relative to the imaging plane. The study by Kandemir et al⁵ lends further support to the influence of measurement technique. They found significant differences between measurement techniques when glenoid inclination angle was measured using both 2D (radiographs) and 3D (manual digitizing) techniques.⁵ The custom software used in the current study for identifying anatomic landmarks operated on a 3D CT-based bone model that could be resized (ie, zoomed) and rotated in 3D as needed. Thus, the technique used in this study for calculating glenoid inclination is not susceptible to out-of-plane imaging errors that are inherent to 2D measurement techniques.

As previously mentioned, it has been theorized that glenoid inclination may have a significant effect on the extent to which the humerus translates superiorly relative to the scapula, as supported by cadaveric experiments. Wong et al¹³ demonstrated that the amount of force required to produce superior humeral head motion decreased as glenoid inclination increased. Konrad et al⁶ showed a similar result, with superior translation of the humerus decreasing as glenoid inclination decreased. Contrary to these findings, our study failed to detect any statistically significant association between glenoid inclination and the 6 different measures of superior humeral translation. A potential explanation for this discrepancy is that the current study measured glenohumeral joint translation under in vivo conditions, whereas previous studies were based on cadaveric studies, which cannot accurately simulate the muscle and joint forces associated with in vivo conditions. Moreover, it seems overly simplistic to expect that glenohumeral joint motion is dictated by a single anatomic factor such as glenoid inclination. Indeed, Michener et al⁷ have summarized that a wide variety of factors, including muscle

activation patterns, muscle fatigue, scapular motion, posture, and acromial shape, likely influence the development of subacromial impingement.

This study has several limitations. First, we are assuming that motion of the contralateral shoulder of patients with a unilateral rotator cuff tear is characteristic of normal, healthy shoulders. However, previous research demonstrated that only 7.9% of patients (58 of 731) with a unilateral rotator cuff tear have an asymptomatic tear in the contralateral shoulder.¹⁶ Furthermore, the contralateral shoulder of each participant was asymptomatic and was verified by an experienced shoulder surgeon to have normal function. Thus, we are comfortable with our assumption that the contralateral shoulder of this patient population provides a reasonable measure of normal shoulder function in a population of patients that is obviously susceptible to rotator cuff tears.

Another limitation is that scapulothoracic motion was not quantified. This limitation is caused by the field of view of the biplane x-ray system, which is dictated by the size of the system's image intensifiers. We anticipate that future upgrades of our biplane x-ray system will allow us to quantify both glenohumeral and scapulothoracic joint motion simultaneously.

Last, we acknowledge that insufficient statistical power is a potential reason for the lack of an association between glenoid inclination and superior/inferior glenohumeral joint translation.

In summary, this study detected a significant difference in glenoid inclination between the repaired and contralateral shoulders of patients who had surgical repair of a rotator cuff tear. Using an accurate motion measurement technique, the study failed to detect any significant association between glenoid inclination and in vivo superior humeral translation during shoulder abduction. This study did not support the theory that glenoid inclination is responsible for superior humeral translation and the development of subacromial impingement.

References

1. Anderst WJ, Tashman S. A method to estimate in vivo dynamic articular surface interaction. *J Biomech* 2003;36:1291-9.
2. Bey MJ, Kline SK, Zuel R, Lock TR, Kolowich PA. Measuring dynamic in-vivo glenohumeral joint kinematics: technique and preliminary results. *J Biomech* 2008;41:711-4.
3. Bey MJ, Zuel R, Brock SK, Tashman S. Validation of a new model-based tracking technique for measuring three-dimensional, in vivo glenohumeral joint kinematics. *J Biomech Eng* 2006;128:604-9.
4. Hughes RE, Bryant CR, Hall JM, Wening J, Huston LJ, Kuhn JE, et al. Glenoid inclination is associated with full-thickness rotator cuff tears. *Clin Orthop* 2003;86-91.
5. Kandemir U, Allaire RB, Jolly JT, Debski RE, McMahon PJ. The relationship between the orientation of the glenoid and tears of the rotator cuff. *J Bone Joint Surg Br* 2006;88:1105-9.
6. Konrad GG, Markmiller M, Jolly JT, Ruter AE, Sudkamp NP, McMahon PJ, et al. Decreasing glenoid inclination improves function

- in shoulders with simulated massive rotator cuff tears. *Clin Biomech* (Bristol, Avon) 2006;21:942-9.
7. Michener LA, McClure PW, Karduna AR. Anatomical and biomechanical mechanisms of subacromial impingement syndrome. *Clin Biomech* (Bristol, Avon) 2003;18:369-79.
 8. Neer CS 2nd. Anterior acromioplasty for the chronic impingement syndrome in the shoulder: a preliminary report. *J Bone Joint Surg Am* 1972;54:41-50.
 9. Neer CS 2nd. Impingement lesions. *Clin Orthop* 1983;70-7.
 10. Poppen NK, Walker PS. Normal and abnormal motion of the shoulder. *J Bone Joint Surg Am* 1976;58:195-201.
 11. Tashman S, Anderst W. In-vivo measurement of dynamic joint motion using high speed biplane radiography and CT: application to canine ACL deficiency. *J Biomech Eng* 2003;125:238-45.
 12. Tetreault P, Krueger A, Zurakowski D, Gerber C. Glenoid version and rotator cuff tears. *J Orthop Res* 2004;22:202-7.
 13. Wong AS, Gallo L, Kuhn JE, Carpenter JE, Hughes RE. The effect of glenoid inclination on superior humeral head migration. *J Shoulder Elbow Surg* 2003;12:360-4.
 14. Wu G, Siegler S, Allard P, Kirtley C, Leardini A, Rosenbaum D, et al. ISB recommendation on definitions of joint coordinate system of various joints for the reporting of human joint motion—part I: ankle, hip, and spine. International Society of Biomechanics. *J Biomech* 2002;35:543-8.
 15. Yamaguchi K, Sher JS, Andersen WK, Garretson R, Uribe JW, Hechtman K. Glenohumeral motion in patients with rotator cuff tears: a comparison of asymptomatic and symptomatic shoulders. *J Shoulder Elbow Surg* 2000;9:6-11.
 16. Yamaguchi K, Tetro AM, Blam O, Evanoff BA, Teefey SA, Middleton WD. Natural history of asymptomatic rotator cuff tears: a longitudinal analysis of asymptomatic tears detected sonographically. *J Shoulder Elbow Surg* 2001;10:199-203.